

## Classification systems for ankle fractures

*Classification systems are only of value if they predict outcome and influence management.*

The classification of ankle fractures has a long and varied history. After Pott's fracture was described in London in the second half of the 18<sup>th</sup> century, most of the work was carried out in Paris. With an unlimited supply of fresh cadaver material (*think 1790s, France, revolution, guillotine etc*), Dupuytren and his students applied controlled mechanical forces to the ankle and dissected and visualized the bone and soft-tissue injuries they had produced. The results of their experiments identified categories of fractures to which their names were applied. Over the years, various ankle fracture classification systems have been developed, including the Pott, Dupuytren, Le Fort, Lauge-Hansen and Weber systems.

### Pott's Fracture (1768)



**Percival Pott** described ankle fractures several years after apparently sustaining one himself in 1756 (although he actually had a compound distal tib/fib fracture, rather than an ankle fracture *per se*).

The classification was based on clinical findings.

(impressive considering Roentgen didn't 'invent' the X-ray until 1895). Quite simply

A **first degree** Pott's fracture has one fractured malleolus,

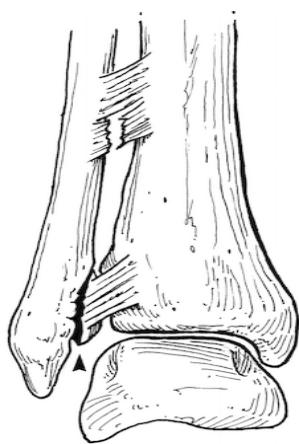
A **second degree** Pott's fracture is bimalleolar

A **third degree** fracture also has a 'posterior malleolar' #.

### Dupuytren Fracture.

Dupuytren fracture is an archaic term used for many types of bimalleolar ankle fractures. The term is commonly used to refer to a fracture of the distal portion of the fibula above the lateral malleolus, with an associated tear of the tibiofibular ligaments and the deltoid ligament. There is lateral displacement of the talus and a possible medial malleolus fracture as well. (ie a **Weber C** fracture – see below)

Guillaume Dupuytren (1777–1835) was the greatest French surgeon of the 19<sup>th</sup> century, with his name being associated with 12 different conditions or operations. He studied fracture healing and carried out extensive experiments on cadavers to elucidate the mechanism of fractures about the ankle. He was known as "*the greatest of surgeons and the meanest of men*".



### Le Fort Fracture of the Ankle

The Le Fort fracture of the ankle is a vertical fracture of the anterior medial portion of the distal fibula, with avulsion of the anterior tibiofibular ligament.

Leon Clement Le Fort (1829–1893) was a distinguished French

surgeon. (But it was his *nephew* Rene who famously classified facial fractures by dropping cadaver heads down a lift shaft from different levels).

Today, there are two commonly used classifications, the Lauge-Hansen and the Weber systems. The Lauge-Hansen classification, which uses the mechanism of injury to classify ankle fractures, can be confusing. It uses terminology such as supination and pronation that, when applied to the foot, is often poorly understood, even by experienced orthopaedic surgeons. The Weber classification is the most practical system for orthopaedic surgeons.

Because of the multiplicity of eponyms and other designations for ankle fractures, there is great confusion in their usage. For this reason, the terms that are archaic, poorly defined, and poorly understood should not be used, including the Bosworth, Cotton, Dupuytren, Le Fort, and Pott classifications. The Lauge-Hansen classification should be used only if one is very familiar with its principles.

### **Lauge-Hansen Classification (1950)**

Niels Lauge-Hansen (1899–1976) was a Danish physician who performed classic studies in the 1940s and 1950s using cadaver specimens to elucidate the mechanisms involved in ankle injuries.

The system uses an arcane and somewhat less than ideal description of foot position and motion of the foot relative to the leg to give a fairly accurate portrayal of the injury and the order in which structures are injured. This system was devised from cadaver studies, but has been found to be an accurate portrayal of fractures in real life. More than 95% of ankle fractures fit the Lauge-Hansen classification scheme. The classification scheme uses 2 word descriptors. The first word describes the position of the foot, the second word describes the motion of the foot (talus) with respect to the leg.

#### **Supination-Adduction**

- Stage 1:** Transverse fracture of lateral malleolus, at or below the level of anterior talo-fibular ligament or a tear of lateral collateral ligament structures with the anterior talo-fibular ligament disrupted most often and frequently the calcaneo-fibular ligament also being torn.
- Stage 2:** + Oblique fracture of medial malleolus.

#### **Supination-External (Eversion) Rotation**

- Stage 1:** Rupture of anterior inferior tibio-fibular ligament.
- Stage 2:** + Oblique fracture or spiral fracture of the lateral malleolus.
- Stage 3:** + Rupture of posterior tibio-fibular ligament or fracture of posterior malleolus of tibia.
- Stage 4:** + Transverse (sometimes oblique) fracture of medial malleolus.  
(40% - 70% of all ankle fractures.)

#### **Pronation-Abduction**

- Stage 1:** Rupture of the deltoid ligament or transverse fracture of the medial malleolus.
- Stage 2:** + Rupture of the ant and post inferior tibio-talo-fibular ligaments or avulsion.
- Stage 3:** + Oblique fracture of the fibula at the level of the syndesmosis.  
(Less than 5% of ankle fractures.)

#### **Pronation-Eversion**

- Stage 1:** Rupture of the deltoid ligament or transverse fracture of the medial malleolus.
- Stage 2:** + Rupture of the anterior inferior tibiofibular ligaments or bony avulsion.
- Stage 3:** + Spiral/Oblique fracture of the fibula above the level of the syndesmosis.
- Stage 4:** + Rupture of the post inf tibio-fibular ligament or fracture of the posterior malleolus.

#### **Pronation-Dorsiflexion**

- Stage 1:** Fracture of the medial malleolus.
- Stage 2:** + Fracture of the anterior lip of the tibia.

- Stage 3:** + Fracture of the supramalleolar aspect of the fibula  
**Stage 4:** + Rupture of the post inf tibiofibular ligament or fracture of the posterior malleolus.

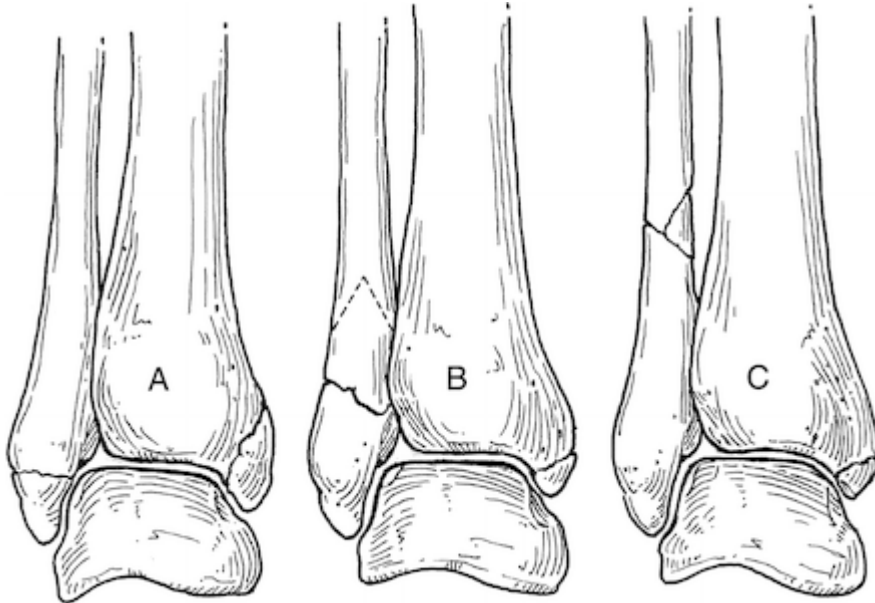
To summarise, this system is best left to senior orthopaedic trainees preparing for *their* exit exam....

## Danis-Weber Classification (1990)

Robert Danis (1880–1962), a Belgian surgeon, was a seminal figure in the development of internal fixation of fractures. He published in 1949 but his work was largely ignored at the time, but rescued and adapted by....

Bernhard Georg Weber (1929– ) is a prominent orthopaedic surgeon in St Gall, Switzerland.

The Danis-Weber classification (which is similar to the AO (Arbeitsgemeinschaft für Osteosynthesefragen) classification system) describes the position of the fracture on the fibula, and by inference, reflects the stability of the mortise. The commonest system for classifying ankle fractures, it is known more commonly as the Weber classification



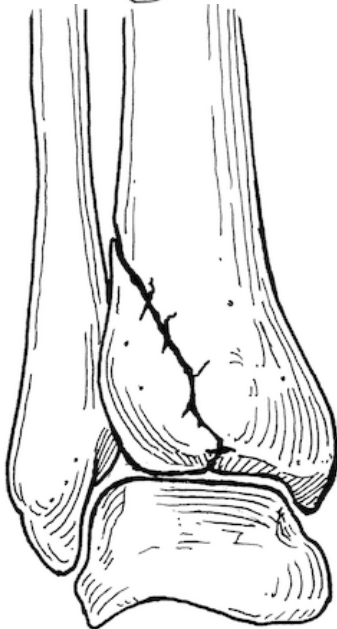
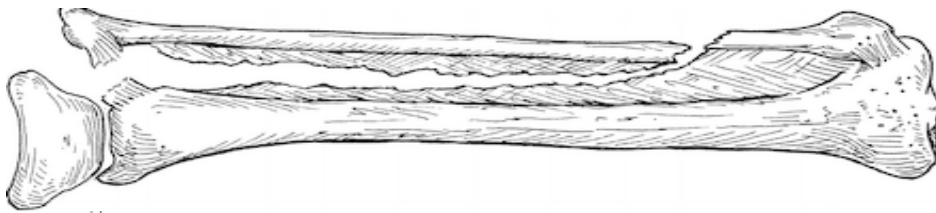
- Type A:** Fracture distal to the syndesmosis (diastasis/distal tibio-fibular ligament).  
Will almost always be stable  
Can be managed conservatively, and won't need to be seen in clinic for a week or so  
*If there is an associated tibial fracture, the classification fails, and an orthopaedic opinion should be sought*
- Type B:** Fracture at the level of the syndesmosis  
May be stable, but may not be. If the fracture is undisplaced, hence stable, it can be managed strictly **non-weight-bearing** in a POP, and should be seen in the next clinic for rexrax. If there is any doubt seek an immediate opinion
- Type C:** fracture above the joint level which tears the syndesmotic ligaments.C  
Will almost always be unstable, so even if a good position is seen on X-ray, it will be a significant injury that merits an immediate orthopaedic opinion.

There are several specific fractures about which we should be aware

## **Maisonneuve Fracture**

The Maisonneuve fracture (*Jacques Gilles Maisonneuve (1809–1897) – Parisian - apparently a student of Dupuytren, although the dates don't quite add up*) is a spiral fracture of the upper third of the fibula associated with a tear of the distal tibiofibular syndesmosis and the interosseous membrane. A variety of Weber C fracture therefore. There is an associated fracture of the medial malleolus or rupture of the deep deltoid ligament.

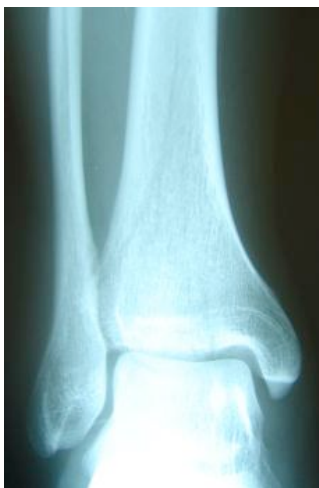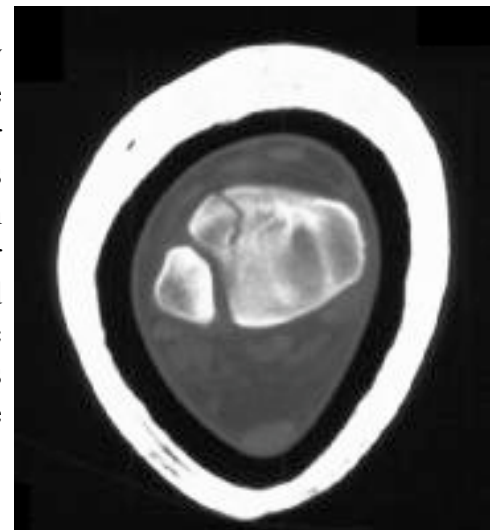
The implication for A&E is that we should x-ray the whole lower leg if there is a fracture of the medial malleolus and no lateral injury is identified on the ankle view.



## **Fracture.**

A Tillaux fracture is an avulsion injury of the anterior tibial tubercle at the attachment of the distal anterior tibiofibular ligament. Paul Jules Tillaux (1834–1904) was a French surgeon and anatomist. Tillaux never clinically described the fracture named for him, but he did exquisite anatomic studies detailing the results of various experimentally produced ankle injuries.

## **Tillaux**

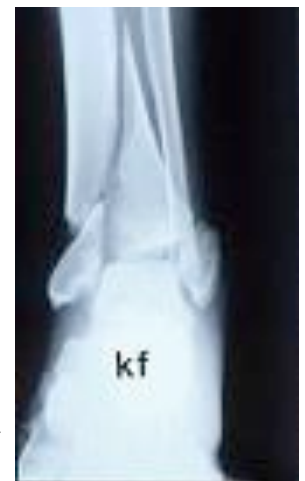

## **Pilon (Tibial Plafond) Fracture**

The term pilon (hammer) fracture was introduced to describe these compression injuries by Destot in 1911; It is an injury sustained from vertical loading driving the talus into the distal tibia; the fibula can also fracture in 20% cases, and 20% are compound.

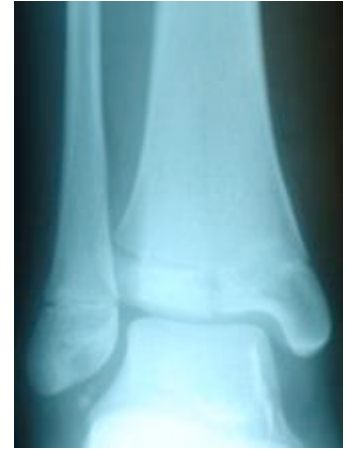They have a high complication rate; 30% will have ipsilateral injuries and 5-10% will have bilateral injuries. It is an 'ankle' fracture which can cause a compartment syndrome.

They are not always obvious radiologically



## Salter Harris fractures

All types of Salter Harris injury may involve the distal tibia or fibula. Most simple Salter Harris fractures of the distal tibia are type 2 but be aware of type 3, (this is the commonest place for a SH3#).



## Alcohol and Ankle Fractures

Drinkers put themselves at risk for a variety of reasons.

### Being *drunk*

- makes people unsteady.
- makes people attempt unrealistic and ill-advised achievements.
- makes people 8 times more likely to be hit by cars
- makes people less likely to put their arms out to stay a fall
- lessens muscle tone, allowing easier dislocation of joints.
- provides excellent analgesia, so the pain of an injury may not be felt until the morning after

### Being an *alcoholic*

- leads to osteoporosis, so a minor fall can cause significant injury.
- can give a peripheral neuropathy so that the pain of an injury is not felt
- makes people reluctant to come to hospital
- provides ongoing analgesia.

So, alcoholics tend to present late with injuries, occasionally managing to walk on fractures that would in normal circumstances be regarded as gross injuries (ie compound fracture-dislocations of the ankle).

As such the threshold for x-raying alcoholic patients should be reduced. (This advice can be extended to those with other causes of impaired responsibility, ie dementia, drugs, mental illness etc.)

More fractures are missed by not being considered in the first place than by not being spotted on x-ray. This often leads to potentially harmful advice, and a clinically significant delay in reaching a correct diagnosis. More people complain following misdiagnosis without x-ray, than after being recalled the next day with a missed fracture on x-ray